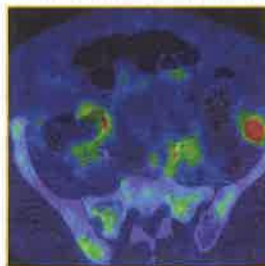
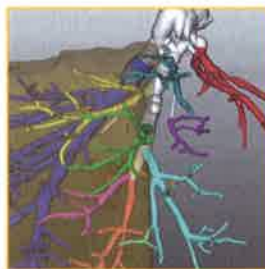
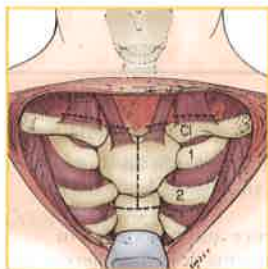


Ref  
WI  
900  
S5241  
2013  
v. 1

# Shackelford's **SURGERY** *of the* **ALIMENTARY** **TRACT**

SEVENTH  
EDITION



VOLUME  
**1**

**Charles J. Yeo, MD**

Samuel D. Gross Professor and Chairman

Department of Surgery

Thomas Jefferson University

Philadelphia, Pennsylvania

JOHN LATHROPE HEALTH SCIENCE LIBRARY

MORRISTOWN MEMORIAL HOSPITAL

100 MADISON AVE.

MORRISTOWN, NJ 07960-1998

ELSEVIER  
SAUNDERS

## Suturing, Stapling, and Tissue Adhesives

Irene Silberstein

Rolando Rolandelli

Wound healing proceeds in a stepwise, time-dependent fashion. The same is true of a healing bowel anastomosis. When the bowel is surgically transected, there is an immediate inflammatory response elicited by activation of the clotting cascade and by recruitment of platelets. The inflammatory cascade is propagated via the release of inflammatory mediators stored in platelet granules. Neutrophils are subsequently mobilized into the wound. This inflammatory phase of wound healing lasts for the first 2 to 5 days following transection. At this time, the collagen matrix is degraded by collagenases and metalloproteinases. It is during this initial phase that the integrity of the anastomosis depends almost entirely on the mechanical sealing of the lumen by sutures or staples.<sup>1</sup>

Collagenolysis is necessary to create a local pool of amino acids, especially those unique to collagen—proline and lysine. The newly formed collagen “recycles” these amino acids. The extent of collagenolysis varies among tissues. Collagenolysis proceeds along the sides of the wound for variable distances. These tissues undergoing collagenolysis around the wound become weaker than normal tissue and are the site most susceptible to failure in the early phases of wound healing. It has been shown that in a colonic anastomosis there is more collagenolysis than in gastric or small bowel anastomosis.<sup>2</sup>

Around the fifth postoperative day there is a transition from the inflammatory phase to the proliferative phase of wound healing. With the proliferation of fibroblasts, there is a shift from collagen degradation to collagen deposition. Day 7 represents the point where the fibroplasia phase reaches its maximal level.<sup>3</sup> It is at this crucial time that any imbalance can result in the potentially catastrophic consequence of anastomotic dehiscence that becomes clinically evident as an abscess, ileus, peritonitis, or fistula.<sup>4</sup>

Once collagen deposition predominates over collagenolysis, the approximation of the two ends of bowel is no longer dependent on sutures or staples but on the cellular matrix surrounding the collagen fibers. It is important to recognize that the time frames of tissue healing stages are shifted by factors impairing wound healing. Corticosteroids, chemotherapeutics, and antirejection medications attenuate and prolong the inflammatory phase. Antiangiogenic drugs and nutrient deficiencies extend collagenolysis and blunt collagen synthesis. Similarly, the presence of local infection intensifies collagenolysis. Consequently, the selection of materials, sutures, and/or staples should be made with consideration to these factors. For instance, suture material that is reabsorbed in less than 3 weeks, such as chromic catgut, may be preferable in cases where none of these factors exist as the material is no longer needed beyond 7 days. Conversely,

in a transplantation patient requiring bowel anastomosis, polyglyconate sutures may be a more appropriate choice as complete healing may take more than 3 weeks.

Malnutrition is often blamed for the failure of intestinal anastomoses. While implicating malnutrition in poor wound healing makes some intuitive sense, the evidence for failure of bowel anastomosis from malnutrition is quite weak. One way of linking malnutrition to poor surgical outcomes is through the tight correlation of hypoalbuminemia with poor outcomes, including failure of bowel anastomoses. However, it is well recognized that hypoalbuminemia is a marker of much broader physiologic derangements than just malnutrition. To achieve poor wound healing in animal experiments, one needs to induce such a state of malnutrition that the animals are moribund from protein depletion. Even then the body prioritizes visceral wound healing over most other sources of protein consumption, including parietal wound healing. Therefore, in cases of emergency surgery when the only “risk” factor of poor wound healing is malnutrition, we would not hesitate to create a bowel anastomosis, albeit with what we believe is the safest technique (double-layer hand-sewn). In these cases, we worry more about the healing of an abdominal wound and may protect the wound with retention sutures.

Although in the industrialized world it may seem that surgical stapling devices have completely supplanted hand-sewn anastomoses, hand suturing remains a crucial skill in every surgeon’s armamentarium. Even in industrialized countries it is becoming too expensive to use the many disposable devices made for construction of bowel anastomoses (e.g., purse-string applicators in addition to staplers). With very few exceptions, such as an ultralow coloproctostomy, the use of stapling has not shown superiority in clinical outcomes, although it is certainly more convenient and expeditious. However, certain situations are not amenable to surgical stapling (e.g., in reoperations where the bowel can be mobilized safely only enough for an end-to-end anastomosis but not for a “functional” end-to-end anastomosis), and it is in these situations that the surgeon’s facility with suturing techniques can vastly affect the outcome of an operation requiring an intestinal anastomosis.

### SURGICAL SUTURING AND TECHNIQUE

As with any other skill, hand-sewing of an intestinal anastomosis requires practice. Having observed or done a few hand-sewn intestinal anastomoses under direct supervision does not allow for the development of the skills necessary to perform an anastomosis, particularly in critical situations (i.e., any situation where a surgeon skilled at stapling cannot use staplers). Therefore, it is to

everyone's advantage (patient, surgeon, and operating team) to perform hand-sewn anastomoses in straight-forward cases. As it is discussed in Techniques and Pitfalls in Surgical Stapling, later, hand-sewn end-to-end enteroenterostomies are physiologically superior to stapled "functional" end-to-end anastomoses. Unless time is of the essence for the patient's survival, for example, a patient with multiple injuries, we believe that most enteroenterostomies should be hand-sewn. In this manner, when the difficult gastrojejunostomy or coloproctostomy comes about, the surgeon is familiar with placing sutures on the bowel and tying them.

## SUTURE MATERIAL

With the exception of stainless steel, which has been largely abandoned for surgeons' safety, all sutures produce some degree of tissue reaction. The degree of inflammation corresponds to the amount of collagenases and metalloproteinases produced in the local wound environment and this determines the subsequent loss of tensile strength in both the wound and the suture material itself.<sup>5</sup>

The type of suture used has traditionally been tailored to the particular enteric wall layer and location within the intestinal tract. Intestinal anastomoses are usually performed in a two-layer fashion. The inner layer consists of an absorbable suture material such as chromic cat gut, polyglactin, or polyglycolic acid, while the outer seromuscular layer utilizes nonabsorbable suture, most commonly silk.

Polyglactin and polyglycolic acid sutures are used interchangeably with chromic catgut, but have the added benefits of decreased inflammatory response and increased strength. The downside of these sutures is that they are braided, producing more drag across the intestinal wall, and may harbor bacteria in their interstices. Silk suture is still the traditional nonabsorbable suture most commonly used for intestinal anastomoses, and it was lauded as the most reliable suture by Halsted as far back as 1913.<sup>6</sup>

Bilioenteric anastomoses present the additional challenge of immediate bile flow, which, by nature of its low surface tension, can leak through minute spaces. Because they only accept one layer, they are commonly performed with more durable absorbable synthetic monofilaments. Because chromic catgut is reabsorbed between 18 and 21 days, it is not the material of choice for single-layer applications such as bilioenteric anastomoses.<sup>7</sup> The absorbable synthetic monofilament sutures of polydioxanone and polyglyconate are the commonly used sutures in these anastomoses because of their longer retention time in wounds and sustained breaking strength.

In conclusion, in two-layer anastomoses, the inner layer is usually an absorbable suture such as chromic catgut, Dexon, or Vicryl, with the outer seromuscular stitch being silk. If a one-layer anastomosis is to be performed, either a nonabsorbable suture, such as silk, or a long-lasting absorbable suture can be used.

## SUTURE MATERIAL AND CELL ADHERENCE

It has been hypothesized that suture material can potentiate bacterial infection in an intestinal anastomosis.

Assuming that suture materials can encourage bacterial infection, a potential mechanism for such a phenomenon could be bacterial adherence to the suture material.

Chu and Williams examined 10 types of suture, ranging from absorbable to nonabsorbable, monofilament to braided, and synthetic to natural origins, and quantitatively determined the adhesion of radiolabeled bacteria to these various sutures. They found that polydioxanone sutures exhibited the lowest affinity to the adherence of *Escherichia coli* and *Staphylococcus aureus*. Dexon sutures exhibited the highest affinity to these species.<sup>8</sup>

Katz et al both confirmed these results and demonstrated via an in vivo model of wound infection that suture materials potentiate bacterial growth and cause infection in mice. They injected suspensions of staphylococci into subcutaneous pockets in mice and found that  $10^9$  bacteria were necessary to cause wound infection in mice in the absence of suture, whereas only  $10^5$  were necessary to elicit significant wound infection in the presence of suture. They also found that the inflammatory response and infectivity scores correlated nicely with the adherence indices of the various types of suture. The fastest removal of bacteria was from nylon and the slowest was from silk.<sup>9</sup> Although no clinical study has yet proven this hypothesis, consideration should be given to the type of suture used in the event of gross fecal soilage.

Manufacturers of suture material have proposed that the ability of sutures to repel bacteria can have an impact on the healing of an intestinal anastomosis. Although this may intuitively seem to have some validity, it has not been supported by any science. The bowel wall seems perfectly capable of handling luminal bacteria even when sutures or staples are used in suboptimally prepared bowel.

This concern of potential infectivity through suture material has led manufacturers of suture materials to add germicides and antibiotics to the sutures. One problem with this approach is the effect of these agents on the inflammatory and fibroplastic process. By attenuating this process, anastomotic healing may be impaired.

An alternative approach has been to locally modulate collagenolytic activity by introducing metalloproteinase inhibitors such as doxycycline into suture material. Pasternak et al utilized a rat model to show that matrix metalloproteinase inhibitor-coated sutures improves tissue integrity and increases breaking strength during anastomotic repair.<sup>10</sup>

Both in vitro and animal data support the theory that certain suture materials support the growth of tumor cells more than others.<sup>11</sup> Using a rodent model, Reinbach demonstrated that radiolabeled tumor cells adhered more avidly to silk suture used to close enterotomies of the colon than they did to polydioxanone sutures (PDS).<sup>12</sup> Further investigation is obviously warranted before deciding which suture truly conveys an oncologic advantage in bowel anastomoses.

## METHODS OF SUTURING

Suture lines can be created either in a simple or interrupted fashion or in a continuous running manner. The advantage of a continuous suture is that the suture line

is more watertight with the disadvantage being that the integrity of the entire suture line is based on one stitch. Hemostasis is also improved with a continuous suture with the converse effect being that continuous suturing may constrict anastomotic blood flow leading to ischemia and anastomotic dehiscence.

Regardless of whether the suture is run in continuous or interrupted fashion, a bowel anastomosis must adhere to the following principles: the anastomosis must be watertight and must have mucosal apposition; the submucosa, which supplies much of the strength to a bowel anastomosis, must be incorporated into the closure; and care must be taken not to strangulate or instrument the edges of the bowel during closure in order to avoid stricture or necrosis and subsequent anastomotic leakage. A lack of tension, or distraction, on suture lines is a must.

### Lembert Suture

Lembert suture is the most commonly used suture in gastrointestinal surgery (Figure 73-1). It is used as the outer layer of a two-layer bowel anastomosis and is also used to repair seromuscular tears in the bowel wall. The stitch is started approximately 3 to 4 mm lateral to the incision and placed at a right angle to the long axis of the incision. It incorporates only the seromuscular layer; care must be taken to not incorporate the full thickness of the bowel wall. The tip of the needle is brought out

close to the edge of the incision and is then reinserted in the apposing wound edge and brought out 3 to 4 mm lateral to the wound edge. The suture is then tied down to a tension that approximates the tissue, but not tight enough to tear the tissue. The most commonly used material for a Lembert suture is either silk or PDS. This stitch can be performed in an interrupted or continuous manner.

### Horizontal Mattress Suture (Halsted Suture)

A horizontal mattress suture, or Halsted suture, is predominantly used for seromuscular apposition in multi-layer bowel anastomoses (see Figure 73-1). The suture is passed through the seromuscular layer 2 to 3 mm lateral to the wound edge and brought out at the wound edge; the needle is then passed through the opposing edge of the wound and brought out 2 to 3 mm lateral. On that same side of the wound, approximately 2 mm distal, the suture is passed through both edges of the wound to create two free ends of the suture on one side of the wound edge with the loop of the suture on the other side. This stitch is particularly useful in damaged, inflamed, or abnormal tissue where a Lembert suture pulls through the tissue. Because the horizontal mattress stitch distributes tension in a plane perpendicular to that of a Lembert suture, it allows for apposition of tissues with a less crushing effect on them.

### Purse-String Suture

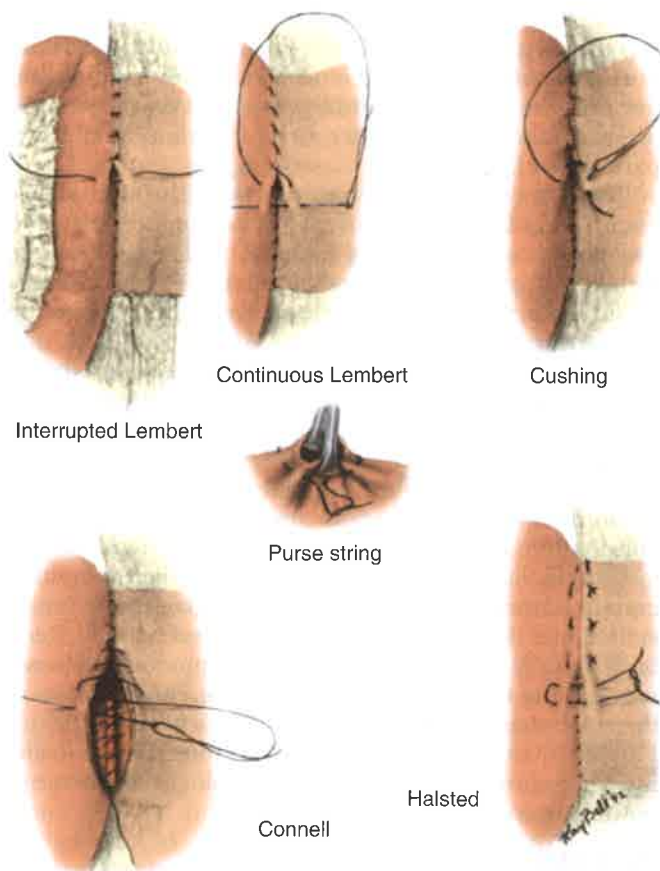
A purse-string suture is used to invert appendiceal stumps or to secure feeding tubes or drainage tubes in place. It is basically a circular continuous Lembert suture about a fixed point or opening in the gastrointestinal tract. It is most commonly performed with nonabsorbable suture (see Figure 73-1).

### Connell Suture

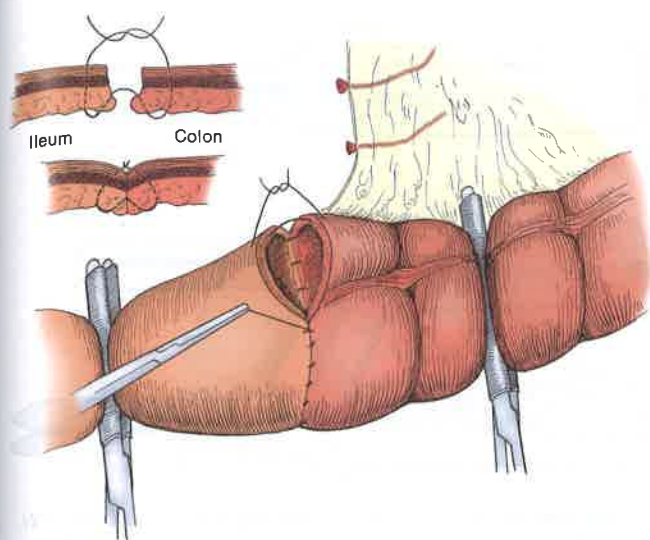
The Connell suture is a full-thickness, usually continuous suture that allows for the mucosa to be inverted into the lumen of a bowel anastomosis (see Figure 73-1). The suture is started at the edge of the anastomosis and brought, full thickness, from inside to out on one side and then outside to in on the opposite side. The suture is tied so that the knot is inside the lumen. The suture is then passed through the tissues from inside to out on one side to begin the Connell stitch. On the other limb of the anastomosis the suture is driven through the tissues, full thickness, from outside to in. On the inside of the bowel lumen the stitch is advanced 2 to 3 mm along the wall and then driven through the bowel wall from inside to out on the *same* side. With the suture now on the outside of the bowel, the next pass is performed on the opposite side in an identical manner. This creates a U-shaped, full-thickness, running inverted suture line. It usually serves as an inner layer of a two-layer anastomosis. Absorbable sutures such as chromic or Vicryl are generally used for these applications.

### Gambée Suture

The Gambée suture is an interrupted single-layer suture that inverts the mucosa into the lumen (Figure 73-2). The suture is brought full-thickness from outside to in



**FIGURE 73-1** Common methods of intestinal suturing. (From Orr TG: *Operations of general surgery*, ed 2. Philadelphia, 1949, Saunders.)



**FIGURE 73-2** The Gambee method of intestinal suturing involving the use of interrupted, inverting sutures. (From Gambee LP, Garnjobst W, Hardwick CE: Ten years' experience with a single layer anastomosis in colon surgery. *Am J Surg* 92:222, 1956.)

and then passed back through the mucosa to exit through the submucosal layer on the same side. It is then passed from the submucosa through the mucosa on the opposite limb. The final pass is a full-thickness one from inside to out on this side. The suture is tied extraluminally. This creates a full-thickness, inverting suture line. Absorbable sutures are typically used for this type of anastomosis. Some surgeons prefer the Gambee stitch for closure of a pyloroplasty.


#### Inverted Versus Everted Intestinal Anastomosis

The concept of inverting versus everting intestinal anastomoses has long been debated. The overwhelming majority of hand-sewn anastomoses are currently performed in an inverting fashion in either one or two layers.

In 1956, Gambee et al published a 156-patient series of various large bowel anastomoses in which they used a single-layer, full-thickness, interrupted, inverting technique with silk suture (see Figure 73-2).<sup>13</sup> They reported five deaths as a result of anastomotic leaks with a mortality of 3%. The incidence of all anastomotic complications was 8.6%, with the majority being radiographic leaks that were not clinically evident.

In 1966, Getzen published a clinical series of 136 everted gastrointestinal anastomoses in which only one leak occurred (resulting in death).<sup>14</sup> Getzen compared inverting and everting bowel anastomoses in a canine model. In 293 anastomoses in dogs, there was no evidence of mucocele or fistula formation. Anastomotic edema was more pronounced in the everted group up to 21 days after surgery. The tensile strength of the inverted anastomosis was two-thirds that of the everted group up to 21 days after surgery. Anastomotic strength was comparable in the two groups after 21 days. There were no deaths attributable to everted mucosa.<sup>15</sup>

As with any other wound, the ideal form of intestinal healing is by primary intention. This is accomplished



**FIGURE 73-3** Depiction of the Hüftl stapler. (From Feil W, Lippert H, Lozac'h P, et al: *Atlas of surgical stapling*. Heidelberg, Germany, 2000, Johann Ambrosius Barth.)

when the individual layers of the intestine reconnect at each side of the anastomosis. Of all layers, the submucosa is particularly important because it harbors fibroblasts that will produce the collagen that ultimately holds the anastomosis together. Inversion of the anastomosis presents the ends of mucosa to the lumen where they are further degraded until the submucosa of one side is apposed to the submucosa on the other side. In an everted anastomosis, the exposed submucosa tends to become adherent to any surrounding structure thereby eliciting adhesions and delaying healing into a secondary-intention process.


Trueblood et al developed a model for the measurement of healing intestinal wounds. They showed in a series of 84 rats that inverted closures had superior strength when measuring bursting pressure. Additionally, they had less gross adhesion formations and more prompt return to normal bowel architecture.<sup>16</sup> Gill et al echoed these findings in a rabbit model. Twenty-five in vivo anastomoses were examined and it was found both grossly and histologically that everted mucosa led to adhesion and fistula formation.<sup>17</sup>

## STAPLERS AND STAPLING TECHNIQUES

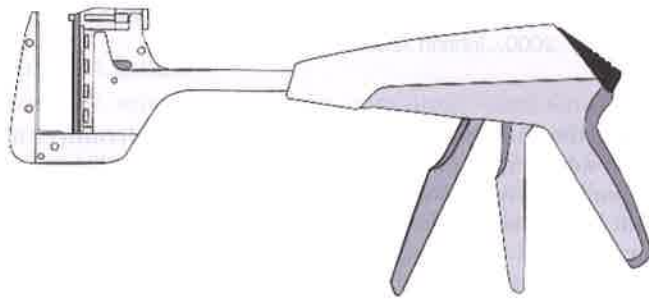
In 1826, Henroz first described a device made from two metal rings that would approximate two open ends of bowel and would then be excreted once anastomotic healing had taken place. He successfully tested the device on dogs.

One of the first stapling devices used in humans was the Hüftl stapler (Figure 73-3). This stapler was used to close the stomach during gastrectomies. The array of staplers now available covers a wide array of anastomoses to be performed via laparotomy or laparoscopically.

Modern-day staplers deliver staples of various staple height. A vascular stapler has a closed staple length of 1 mm. Tissue staplers have "blue" cartridges and "green" cartridges that are used for thin tissues and thick tissues, respectively. The closed staple length of a "blue" stapler is 1.5 mm, and it is used for standard tissues such as the small bowel, colon, and esophagus. The closed staple length of a "green" stapler is 2 mm. These staplers are



**FIGURE 73-4** Vascular staple lines versus intestinal staple lines. (From Feil W, Lippert H, Lozac'h P, et al: *Atlas of surgical stapling*. Heidelberg, Germany, 2000, Johann Ambrosius Barth.)



**FIGURE 73-5** Depiction of a thoracoabdominal stapler. (From Feil W, Lippert H, Lozac'h P, et al: *Atlas of surgical stapling*, Heidelberg, Germany, 2000, Johann Ambrosius Barth.)

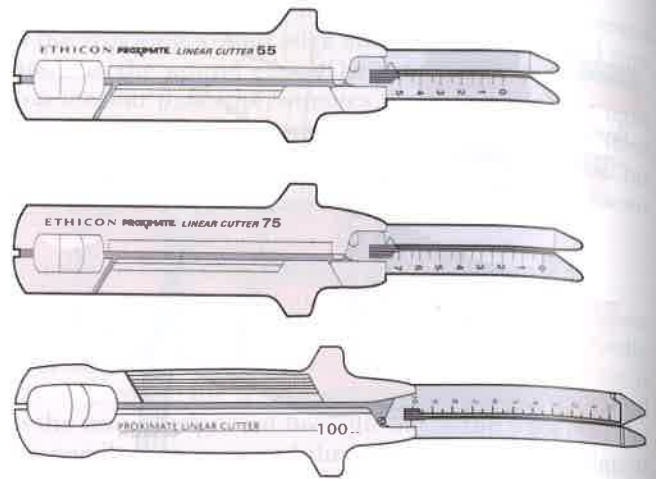
used for thicker tissues such as the stomach or rectum. Some staplers create staple heights within a “firing” range at the point the surgeon believes appropriate, depending on the force used in the approximation of tissues.

Tissue staplers deliver two staggered rows of staples on each side of the divided bowel, whereas vascular staplers deliver three staggered rows of staples on each side and are used to divide large-caliber vessels while maintaining hemostasis (Figure 73-4).


**TYPES OF STAPLERS**

Linear noncutting staplers (e.g., thoracoabdominal [TA] staplers) deliver a double staggered row of staples. They are used in a wide variety of situations including closure of a hollow viscus, such as the common enterotomy in a side-to-side bowel anastomosis, closure of gastrotomies, and division of large vessels (Figure 73-5). Staple length varies and they can be articulating and nonarticulating.

Linear cutting staplers (e.g., gastrointestinal anastomosis [GIA]) both transect and close hollow viscera by delivering two double-staggered rows of staple lines and deploying a knife to divide the tissue between the staple lines (Figures 73-6 and 73-7). They are used for a variety of gastrointestinal procedures, such as the formation of enteroenterostomies and gastroenterostomies, and the resection of solid organs, such as the liver or pancreas. Laparoscopic linear cutting staplers come in different lengths but similar diameter (12 mm). The staple length varies and the instrument is available in both articulating and nonarticulating varieties.



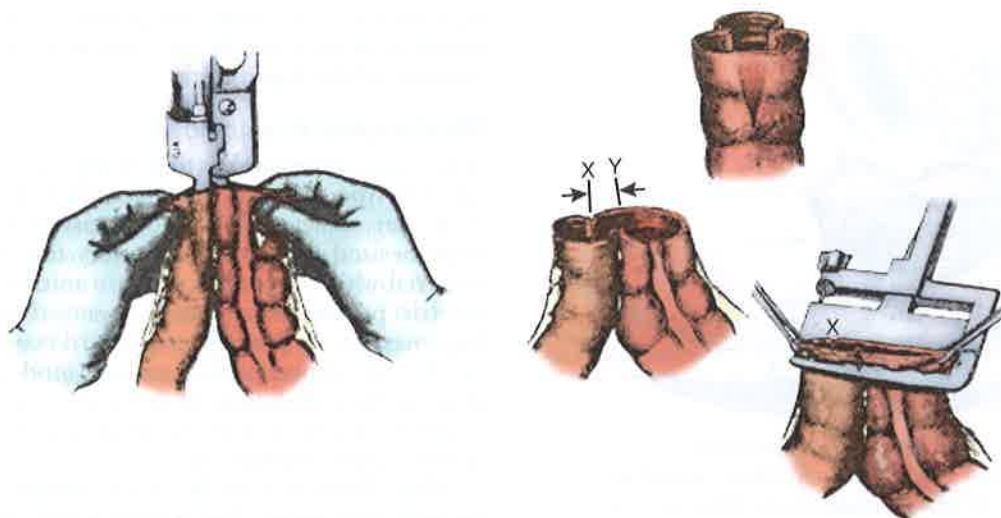
**FIGURE 73-6** Various sizes of linear cutting staplers. (From Feil W, Lippert H, Lozac'h P, et al: *Atlas of surgical stapling*. Heidelberg, Germany, 2000, Johann Ambrosius Barth.)



**FIGURE 73-7** Configuration of the staple lines of linear cutting staplers in relation to the knife. (From Feil W, Lippert H, Lozac'h P, et al: *Atlas of surgical stapling*. Heidelberg, Germany, 2000, Johann Ambrosius Barth.)

Curvilinear cutting staplers (contour stapler) also have two double-staggered staple lines and a knife to divide in between these lines, but the instrument has a curved shape. The staple length is fixed and the stapler is nonarticulating. The contour stapler offers an advantage in a transabdominal proctectomy or very-low-anterior resection of the rectum as it is able to fit into the narrow confines of the pelvis.

Circular staplers (e.g., end-to-end anastomosis [EEA], intraluminal, and procedure for prolapse and hemorrhoid [PPH] staplers) are used for inverted end-to-end and end-to-side anastomoses. These staplers have a detachable head and lay down a circular, double-staggered row of staples. The staples can be variably tightened to a closed length of 2.5 to 1 mm depending on the thickness of the tissue. A special circular stapler with nondetachable shaft (e.g., PPH) is used to excise prolapsed rectal mucosa at the top of the anal canal as a treatment for prolapsing hemorrhoids.



**FIGURE 73-8** Example of a side-to-side, functional end-to-end stapled intestinal anastomosis. When closing the common enterotomy, care must be taken to stagger the anterior and posterior staple lines. (From Chassin JL, Rifkind KM, Turner JW: Errors and pitfalls in stapling gastrointestinal tract anastomoses. *Surg Clin North Am* 64:447, 1984.)

## TECHNIQUES AND PITFALLS IN SURGICAL STAPLING

### Functional End-to-End Anastomosis

A functional end-to-end anastomosis (Figure 73-8), first described in the 1960s, involves apposing the antimesenteric surfaces of two segments of bowel and placing one arm of the GIA stapler in each lumen and firing the stapler to create a common lumen.<sup>18</sup> The lumen is examined and the staple line is checked for hemostasis; bleeding points along the staple line in the lumen may be controlled with fine suture. Application of cautery on the staple lines should be discouraged because the current is transmitted along the length of the staple line and thus can harm otherwise healthy tissue. The common enterotomy is grasped, full thickness, at its edges with Allis clamps to ensure that the serosa and muscularis do not slip under the staple after the stapler is approximated. A single firing of the TA stapler is used to close the common enterotomy. Before firing the TA across the common enterotomy, an important technical point is to ensure that the anterior termination and posterior termination of the GIA staple line are staggered to avoid the crossing of three staple lines.<sup>19</sup> When multiple staple lines cross at the same point, the staples may not close properly, which could lead to anastomotic leakage (see Figure 73-8). The staple line that closes this common enterotomy is actually an everting one and may thus predispose to the formation of adhesions. This may be addressed by placing seromuscular sutures to cover the staple line. Alternatively, the common enterotomy may be closed in an inverting two-layer hand-sewn fashion.

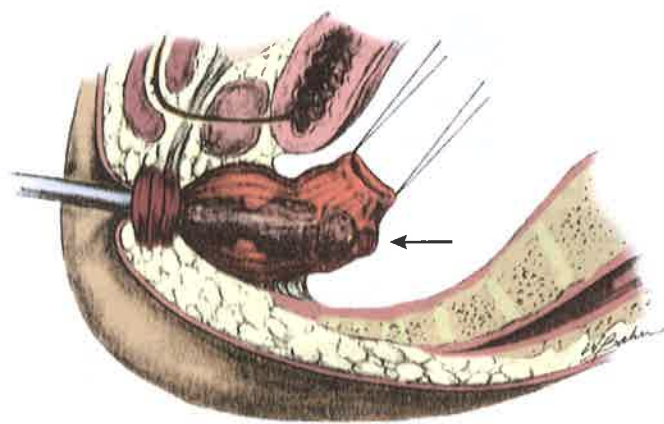
Hocking et al demonstrated in a canine model that creation of a functional end-to-end anastomosis alters small bowel motility to a greater degree than an end-to-end anastomosis and that this may predispose to bacterial overgrowth.<sup>20</sup> Even 2 years after surgery, only 50% of the myoelectrical impulses crossed the functional end-to-end anastomosis. Case reports have also shown that

this dysmotility and bacterial overgrowth can lead to massive luminal dilation and subsequent volvulus.

### Stapled End-to-End Anastomosis

This type of anastomosis is performed with a circular stapler (e.g., EEA) and is commonly used for the creation of a coloproctostomy, but is also used for gastroenterostomies and esophagogastrotomies. In the case of a colorectal anastomosis, the proximal end of the two ends to be anastomosed is opened and EEA sizes are placed into the lumen to assess the size of the stapler to be used. Optimal size for these anastomoses should be either 29 or 31 mm; using a smaller size may predispose to anastomotic stricture. Care should be taken to avoid creating serosal or muscular tears in the colon. Relaxation of the smooth muscle may be attained by administering intravenous glucagon, 1 mg, to prevent these tears. The anvil for the EEA is then placed into the open end of the colon and a monofilament purse-string suture is placed around the rod of the anvil and tied tightly around the rod. Alternatively, an automatic purse-string device may be used, although this may not consistently include the full thickness of the bowel end. Specialized clamps that allow for manual passage of a straight needle through the full thickness of the bowel wall resolve this issue. If there are any gaps in the purse-string suture, the staple line might be incomplete and a leak could ensue. A mattress suture may be placed around the rod to reinforce the purse-string suture. Care must be taken to dissect free any fat that may be incorporated into the staple lines because this may predispose the anastomosis to leakage. The blood supply should also not be too close to the ends for fear of intraluminal bleeding after the stapler is fired.

The stapling device is inserted into the rectum transanally. Care must be taken to follow the contour of the rectum and sacrum to avoid perforating the back wall of the rectum (Figure 73-9) and to avoid incorporating the bladder or the vaginal wall in females. At the top of the



**FIGURE 73-9** When passing a circular stapler for a coloproctostomy, care must be taken to follow the contour of the rectum and sacrum to avoid inadvertently pushing the stapler through the back of the rectum. (From Chassin JL, Rifkind KM, Turner JW: Errors and pitfalls in stapling gastrointestinal tract anastomoses. *Surg Clin North Am* 64:451, 1984.)

rectum, the stapler should be positioned so that the pin of the EEA comes out in the middle of the staple line at the portion of rectum that has been cleaned rather than advancing the pin at any other point such as through the mesorectum. Once the pin is advanced, the anvil and stapler are engaged and the device is closed tightly.

#### Hand-Sewn Versus Stapled Bowel Anastomoses

Beart and Kelly randomized 80 patients to hand-sewn versus stapled coloproctostomies and found no differences in postoperative complications.<sup>21</sup>

In a prospective multicenter randomized study, Docherty et al compared manually constructed and stapled colorectal anastomoses in 732 patients.<sup>22</sup> Despite a significant increase in radiologic leak rates in the sutured group (14% vs. 5%), there was no difference in clinical anastomotic leak rates, morbidity, and postoperative mortality. Univariate analysis, correcting for tumor stage, demonstrated that the rate of tumor recurrence and cancer-specific mortality was higher in the sutured patients (7.5% and 6.5%, respectively) and in patients with anastomotic leaks.

A metaanalysis of 13 studies that examined manual versus stapled colon and rectal anastomoses found no differences in leak rate, morbidity, mortality, and cancer recurrence. It did, however, demonstrate a higher rate of intraoperative technical problems and a higher rate of anastomotic strictures after stapled anastomoses.<sup>23</sup> This higher rate of stricture in stapled anastomoses is counterintuitive based on the fact that in animal models, the blood flow rate through stapled anastomoses is significantly higher than the flow rate through the standard two-layer or Gambee anastomoses.<sup>24</sup>

Another observation in experimental animals is that stapled anastomoses tend to heal by secondary intention as compared with hand-sewn anastomoses which heal by primary intention.<sup>25</sup> This is most noticeable in the functional end-to-end type. Leakage from this anastomosis tends to take place at its closure with the TA stapler and often occurs weeks after being created rather than in the

typical first week. During reoperation, the anastomosis is found to be attached by the everted TA line to some raw surfaces of the laparotomy.

#### Microsurgical Anastomosis

A new area of research is that of microsurgical anastomosis. This type of anastomosis would most closely approximate an exact end-to-end anastomosis. Hart et al hypothesized that by utilizing very fine filament suture material while operating under a microscope, the myoelectric propagation across transected bowel would be improved as compared to a standard two-layer anastomosis. In an experimental animal model, they indeed showed that propagation of pacesetter potentials was restored across a microsurgical anastomosis but not across a conventional one.<sup>26</sup>

There have not yet been any studies evaluating this method in humans, but it does merit further examination as this type of anastomosis may greatly diminish posttransection bowel dysmotility and subsequent bacterial overgrowth.

#### TISSUE ADHESIVES

Ever since the first use of fibrin powder for hemostasis in 1909, the utility of fibrin and fibrin glue products has rapidly increased in a wide spectrum of different areas of surgery.<sup>27,28</sup> Although more commonly used for hemostasis, skin grafting, bone sealing, and other straightforward tissue repairs, its use in the formation of sutureless anastomoses or in the reinforcement of bowel anastomoses is controversial.

Fibrin glue promotes the coagulation of blood by accelerating the conversion of fibrinogen to fibrin. It is generally packaged as two separate vials that need to be mixed immediately before use. The first vial usually contains fibrinogen, factor VIII, and plasma proteins. The second usually contains thrombin, calcium chloride, and aprotinin. As the two components are mixed, factor VIII is activated and fibrin is subsequently crosslinked which results in the hemostatic effect and more importantly has effects of varying degree on wound-breaking strength and tissue adhesion.

Data on fibrin glue reinforcement of surgical anastomoses are inconsistent but suggest a detrimental effect on bowel anastomoses. In a rat model of intestinal anastomosis, sutureless anastomoses performed with fibrin glue were associated with a higher leak rate than traditional sutured anastomoses. Furthermore, the bursting pressure of the fibrin glue anastomoses, when compared with sutured anastomoses, was lower at 4 and 7 days postoperatively, which is the critical period in intestinal healing and is also the period associated with anastomotic leakage.<sup>29</sup>

Reinforcement of intestinal anastomoses with fibrin sealant also has a detrimental effect on anastomotic strength. Van der Ham demonstrated in a rat model that reinforcement of the suture lines in intestinal anastomoses had a detrimental effect on anastomotic strength, bursting pressure, and hydroxyproline content. Thus, these anastomoses were both physiologically and biologically inferior.<sup>30,31</sup> These results were duplicated by Byrne,



who showed quite clearly not only the negative effects on bursting pressure, but also impressive rates of perianastomotic adhesions, toxic sepsis, and death in rats.<sup>32</sup>

Microscopically, there is an intense perianastomotic inflammatory reaction, and levels of hydroxyproline and subsequently collagen are significantly lower in the fibrin glue anastomoses.<sup>30-32</sup> More importantly, high levels of fibrin have been found to inhibit macrophage migration.<sup>33</sup> Fibrin has also been shown to predispose to residual abscess formation in rat peritonitis models. Fibrin inhibits neutrophil phagocytosis of radiolabeled bacteria through a reversible but dose-dependent mechanism.<sup>34</sup> Thus, fibrin not only acts as an inhibitor to macrophage migration but also inhibits neutrophil function and thus can be a potential nidus for bacterial infection. In conclusion, the routine use of tissue adhesives for the reinforcement of bowel anastomoses cannot be recommended.

## ADHESION BARRIERS

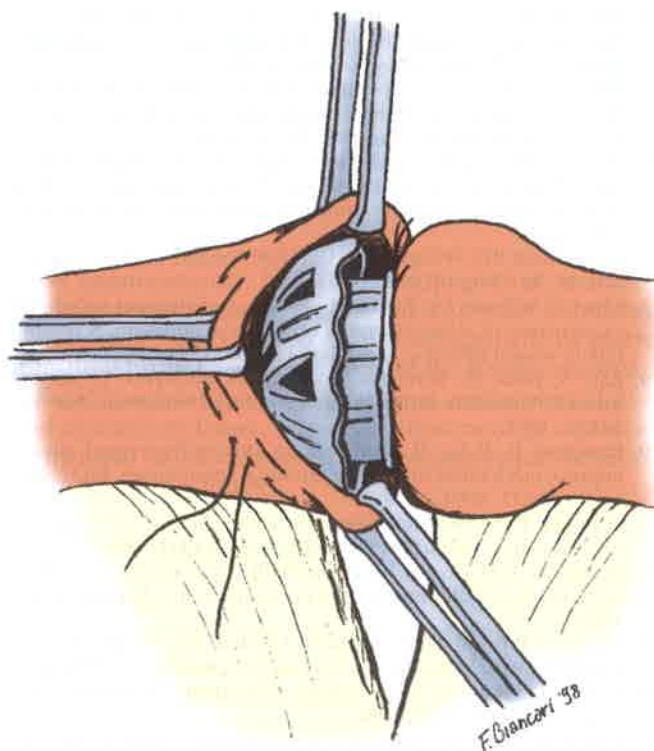
For countless years, there has been a search for an effective barrier to adhesion formation. The problem is that the properties that make an effective barrier will also detrimentally affect a newly created anastomosis. Hyaluronic acid-based absorbable films and meshes have been developed and are the most commonly used materials for adhesion prevention. These membranes mechanically separate adhesiogenic tissue while normal healing takes place. After a few days, the membrane becomes a hydrated gel that absorbs over the course of a week. It has been postulated that hyaluronic acid enhances peritoneal fibrinolysis but this has not been conclusively proven.

An aftermarket study of Seprafilm, a hyaluronic acid-based film, showed that wrapping the suture or staple line of a fresh anastomosis should be avoided because it increased the risk of anastomotic leak.<sup>35</sup>

## BIOFRAGMENTABLE ANASTOMOSIS RING

In 1985, Thomas G. Hardy, Jr. described a biofragmentable anastomosis ring (Valtrac) intended to facilitate sutureless intestinal anastomosis.<sup>36</sup> The device consists of two identical circular rings composed of Dexon and 12% barium sulfate. Prolene sutures are used to create purse-string stitches at the two cut ends of the bowel, and the sutures are tightened around the rings after the rings are placed inside the bowel lumens (Figure 73-10). The device is closed by applying pressure to both sides of the anastomosis. The device is broken down and passed in stool at some later time.

Hardy et al validated the feasibility and safety of this device in a dog model.<sup>36</sup> The safety and efficacy of the Valtrac device for human use was examined in a prospective, randomized, multicenter clinical study. The patients were randomized to sutured or stapled intestinal anastomoses versus use of the biofragmentable anastomosis ring. No difference was found in the postoperative complications of anastomotic leak, fistula, hemorrhage, wound infection, ileus, or small bowel obstruction between groups. There was no advantage or difference



**FIGURE 73-10** Example of the biofragmentable anastomosis ring. (From Di Castro A, Biancari A, Brocato R, et al: Intestinal anastomosis with the biofragmentable anastomosis ring. *Am J Surg* 176:473, 1998.)

in length of stay, diet, or return to bowel function.<sup>37</sup> Therefore, the biofragmentable anastomosis ring was found to be at least as efficacious as traditional sutured or stapled anastomoses.

## CONCLUSION

At the present time it is not possible to categorically state what the ideal method of intestinal anastomosis is for every patient. Therefore, it is up to the surgeon to decide in the course of an operation which method is most appropriate. Although much of this decision-making process is based on well-established scientific principles, part of the decision is also based on the surgeon's skill and experience. Our current inability to scientifically test these factors places them in the realm of art. As in many other biologic processes, further technologic progress will enable us to apply scientific principles even to what is now considered the art of surgery.

## REFERENCES

1. Migaly J, Lieberman J, Long W, et al: Effect of adenoviral-mediated transfer of transforming growth factor-beta1 on colonic anastomotic healing. *Dis Colon Rectum* 47:1699, 2004.
2. Van der Stappen JWJ, Hendricks T, DeBoer HHM: Collagenolytic activity in experimental intestinal anastomoses: Differences between small and large bowel and evidence for the presence of collagenase. *Int J Colorectal Dis* 7:95, 1992.
3. Buckmire M, Parquet G, Greenway S, et al: Temporal expression of TGF-beta 1, EGF, and PDGF-BB in a model of colonic wound healing. *J Surg Res* 80:52, 1998.

4. Fukuchi SG, Seeburger JL, Parquet G, et al: Influence of 5-fluorouracil on colonic healing and expression of transforming growth factor-beta 1. *J Surg Res* 84:121, 1999.
5. Ballantyne GH: The experimental basis of intestinal suturing. Effect of surgical technique, inflammation, and infection on enteric wound healing. *Dis Colon Rectum* 27:61, 1984.
6. Halsted HW: Ligature and suture material. The employment of fine silk in preference to catgut and the advantage of transfixion of tissues and vessels in the control of hemorrhage. *JAMA* 60:1119, 1913.
7. Postlethwait RW, Willigan DA, Ulin LW: Human tissue reaction to sutures. *Ann Surg* 181:144, 1975.
8. Chu CC, Williams DF: Effects of physical configuration and chemical structure of suture materials on bacterial adhesion. A possible link to wound infection. *Am J Surg* 147:197, 1984.
9. Katz S, Izhar M, Mirelman D: Bacterial adherence to surgical sutures. A possible factor in suture induced infection. *Ann Surg* 194:35, 1981.
10. Pasternak B, Rehn M, Andersen L: Doxycycline-coated sutures improve mechanical strength of intestinal anastomoses. *Int J Colorectal Dis* 23:271, 2008.
11. O'Dwyer P: Serum dependent variability in the adherence of tumour cells to surgical sutures. *Br J Surg* 72:466, 1985.
12. Reinbach D, McGregor JR, O'Dwyer PJ: Effect of suture material on tumour cell adherence at sites of colonic injury. *Br J Surg* 80:774, 1993.
13. Gambee LP, Garnjobst W, Hardwick CE: Ten years' experience with a single layer anastomosis in colon surgery. *Am J Surg* 92:222, 1956.
14. Getzen LC: Clinical use of everted intestinal anastomoses. *Surg Gynecol Obstet* 123:1027, 1966.
15. Getzen LC, Roe RD, Holloway CK: Comparative study of intestinal anastomotic healing in inverted and everted closures. *Surg Gynecol Obstet* 123:1219, 1966.
16. Trueblood HW, Nelsen TS, Kohatsu S: Wound healing in the colon: Comparison of inverted and everted closures. *Surgery* 65:919, 1969.
17. Gill W, Fraser SJ, Carter DC: Everted intestinal anastomosis. *Surg Gynecol Obstet* 128:1297, 1969.
18. Steichen FM: The use of staplers in anatomical side-to-side and functional end-to-end enteroanastomoses. *Surgery* 64:948, 1968.
19. Chassin JL, Rifkind KM, Turner JW: Errors and pitfalls in stapling gastrointestinal tract anastomoses. *Surg Clin North Am* 64:441, 1984.
20. Hocking MP, Carlson RG, Courington KR, et al: Altered motility and bacterial flora after functional end-to-end anastomosis. *Surgery* 108:384, 1990.
21. Beart RW, Kelly KA: Randomized prospective evaluation of the EEA stapler for colorectal anastomoses. *Am J Surg* 141:143, 1991.
22. Docherty JG, McGregor JR, Akyol M, et al: Comparison of manually constructed and stapled anastomoses in colorectal surgery. *Ann Surg* 221:176, 1995.
23. MacRae HM, McLeod RS: Handsewn vs stapled anastomoses in colon and rectal surgery: A meta-analysis. *Dis Colon Rectum* 41:180, 1998.
24. Wheeler CR, Smith JJ: A comparison of the flow of iodine 125 through three different intestinal anastomoses: Standard, Gambee, and stapler. *Obstet Gynecol* 62:513, 1983.
25. Caporossi C, Ceconello I, Aguilar-Nascimento JE, et al: Hand-sewn and stapled esophageal anastomosis: Experimental study in dogs. *Acta Cir Bras* 19:319, 2004.
26. Hart SC, Nguyen-Tu BL, Hould F: Restoration of myoelectrical propagation across a jejunal transection using microsurgical anastomosis. *J Gastrointest Surg* 3:524, 1999.
27. Bergel S: Ueber Wirkungen des Fibrins. *Dtsch Med Wochenschr* 35:663, 1909.
28. Detweiler MB: Sutureless and reduced suture anastomosis of hollow vessels with fibrin glue: A review. *J Invest Surg* 12:245, 1999.
29. Haukipuro KA, Hulkko OA, Alavaikko MJ, et al: Sutureless colon anastomosis with fibrin glue in the rat. *Dis Colon Rectum* 31:601, 1988.
30. Van der Ham KA, Kort WJ, Weijma IM, et al: Effect of fibrin sealant on the healing colonic anastomosis in the rat. *Br J Surg* 78:49, 1991.
31. Van der Ham KA, Kort WJ, Weijma IM, et al: Healing of colonic anastomoses: Fibrin sealant does not improve wound healing. *Dis Colon Rectum* 35:884, 1992.
32. Byrne DJ: Adverse influence of fibrin sealant on the healing of high-risk sutured colonic anastomoses. *J R Coll Surg Edinb* 37:394, 1992.
33. Ciano PS, Colvin RB, Dvorak AM, et al: Macrophage migration in fibrin gel matrices. *Lab Invest* 54:62, 1986.
34. Rotstein OD, Pruett TL, Simmons RL: Fibrin in peritonitis: V. Fibrin inhibits phagocytic killing of *Escherichia coli* by human polymorphonuclear leukocytes. *Ann Surg* 203:413, 1986.
35. Beck DE, Cohen Z, Fleshman JW: A prospective, randomized, multicenter study of the safety of Seprafilm adhesion barrier in abdominal pelvic surgery of the intestine. *Dis Colon Rectum* 46:1310, 2003.
36. Hardy TG, Pace WG, Maney JW, et al: A biofragmentable ring for sutureless anastomosis: An experimental study. *Dis Colon Rectum* 28:484, 1985.
37. Corman ML, Prager ED, Hardy TG, et al: Comparison of the Valtrac biofragmentable anastomosis ring with conventional suture and stapled anastomosis in colon surgery. *Dis Colon Rectum* 32:183, 1989.